

## Ocular melanocytosis

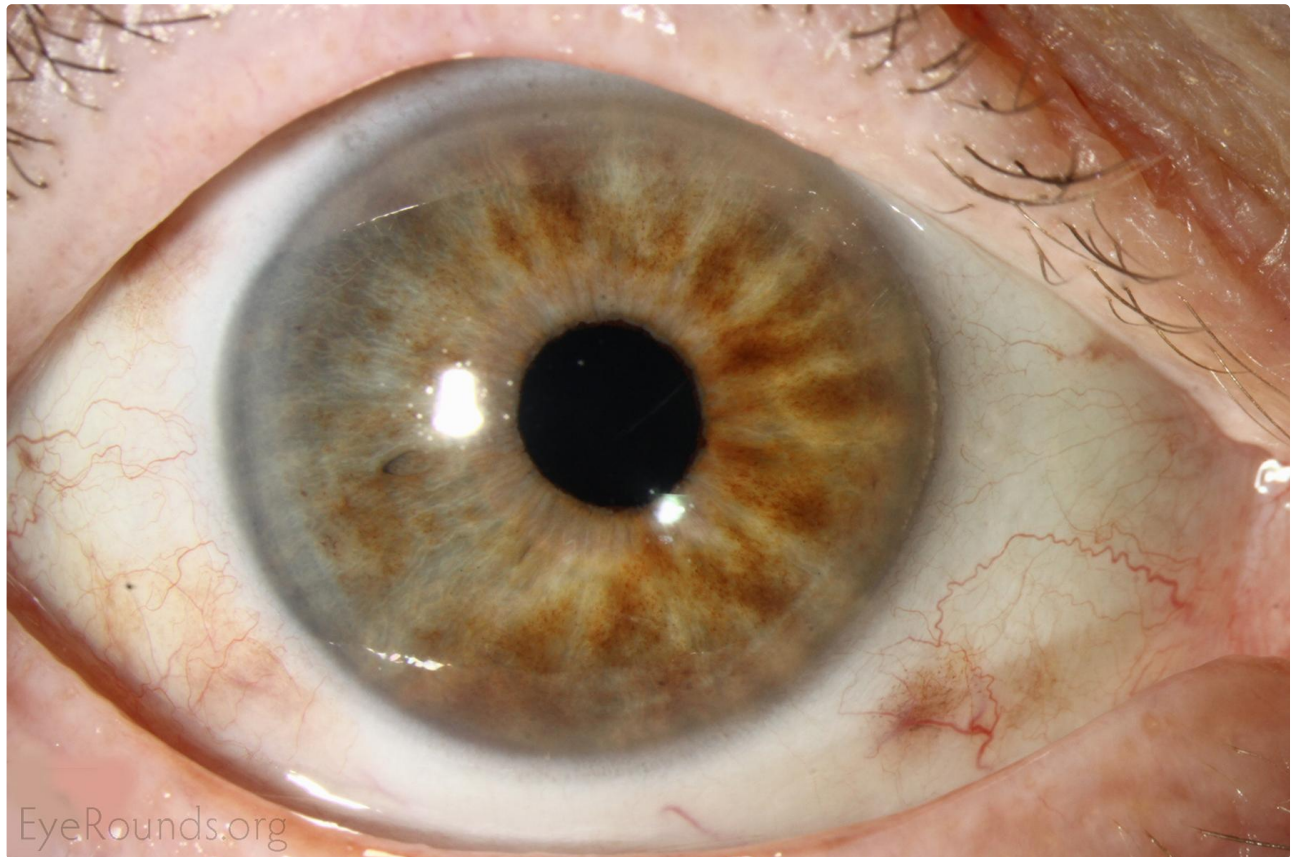Category(ies): Cornea, Glaucoma, Iris, Retina

Contributor: [David Phillips, MD](#)

Photographer: Toni Venckus, CRA



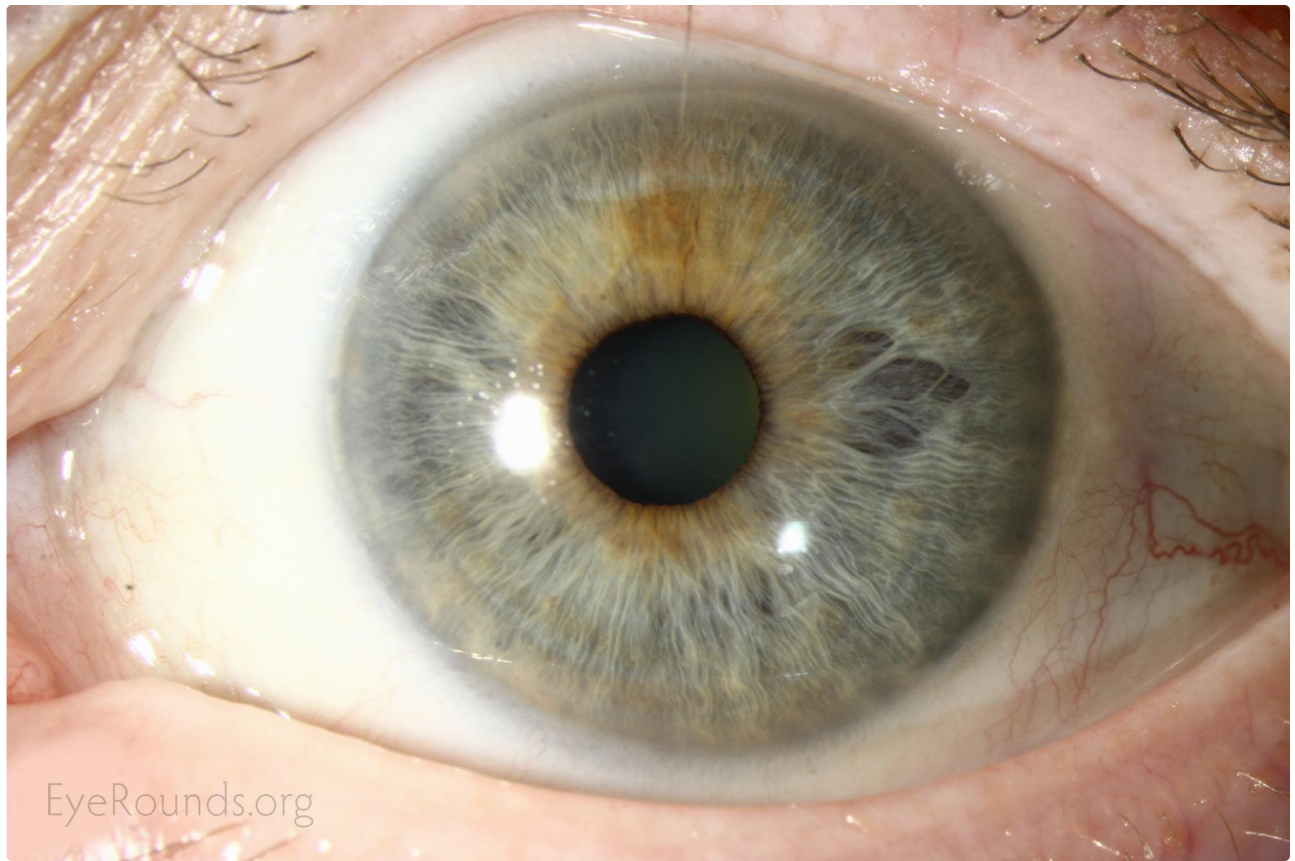
75-year-old patient with ocular melanocytosis in the right eye. Findings include iris heterochromia, and increased pigmentation of angle and fundus when compared to left eye with no dermal involvement. The patient also has dry age related macular degeneration changes in both eyes, peripapillary atrophy, and moderate glaucomatous optic neuropathy as per Humphery visual fields and optic nerve OCT. It was interesting that there was more glaucomatous damage in the left eye, the eye that was not affected with melanocytosis.



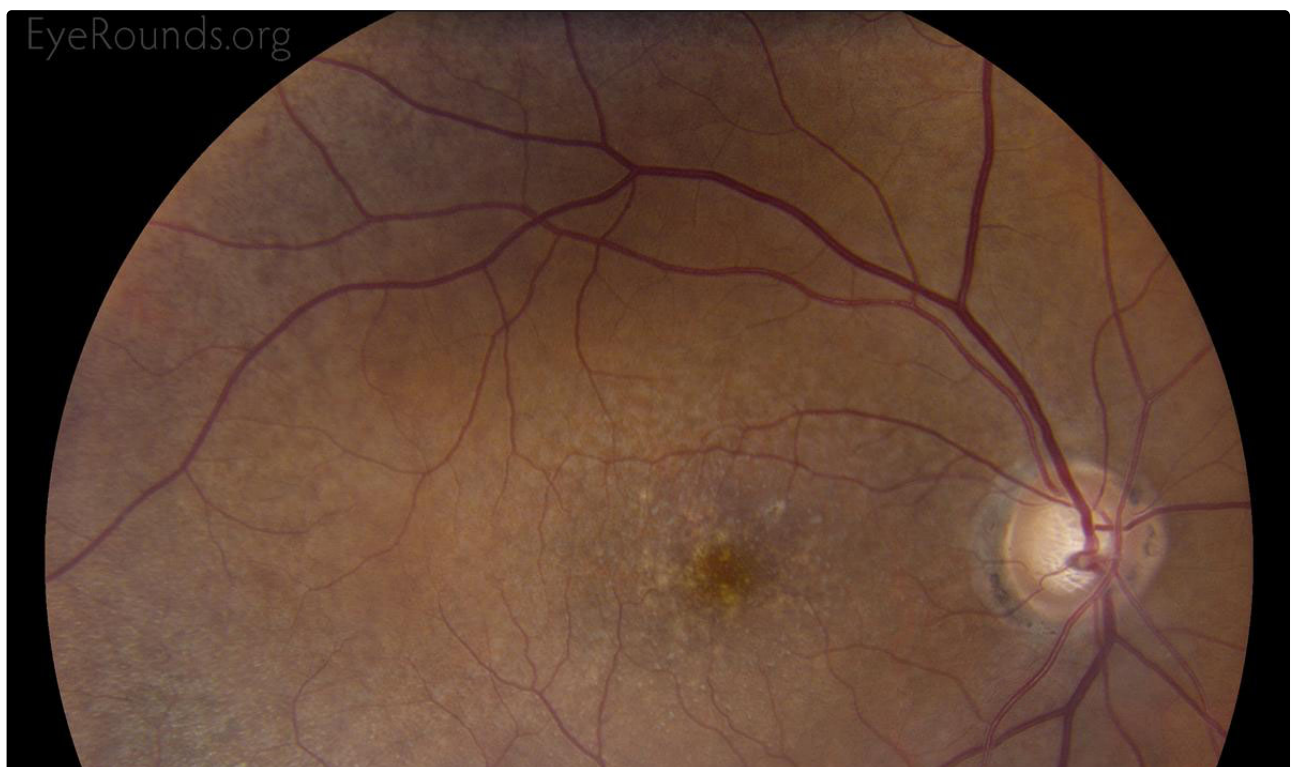EyeRounds.org

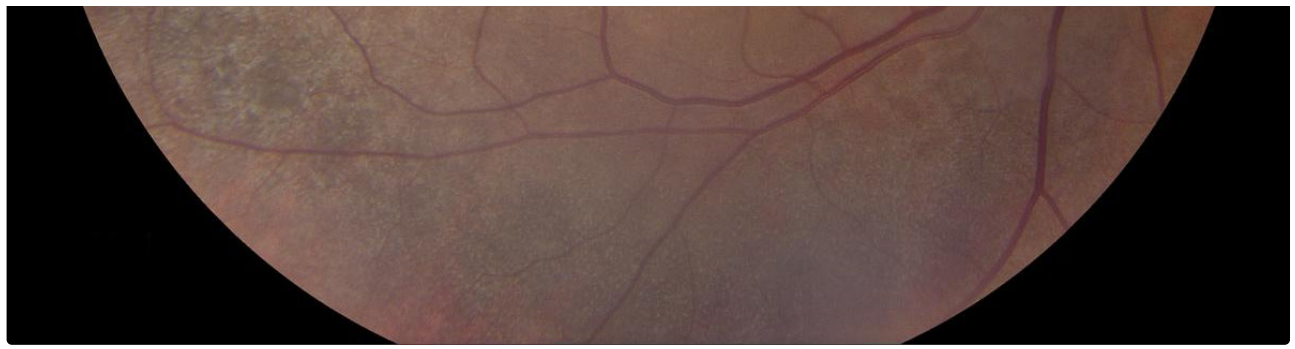
[Enlarge](#)

[Download](#)

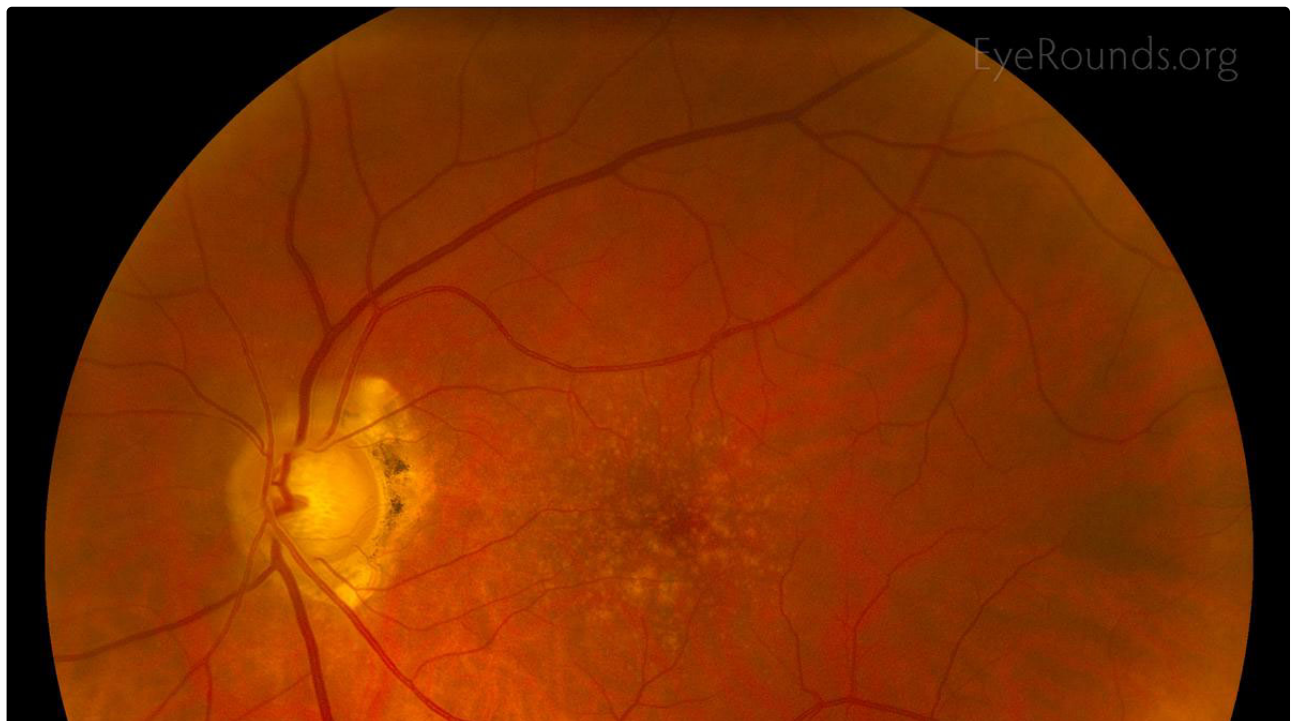


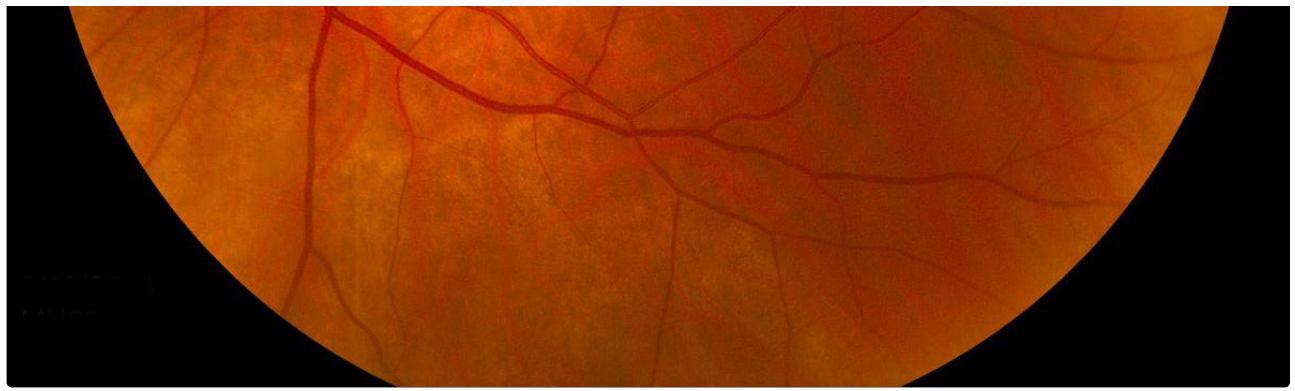
[Enlarge](#) [Download](#)





[Enlarge](#) [Download](#)





 [Enlarge](#)

 [Download](#)

### Image Permissions:



Ophthalmic Atlas Images by [EyeRounds.org](http://EyeRounds.org), [The University of Iowa](http://The University of Iowa) are licensed under a [Creative Commons Attribution-NonCommercial-NoDerivs 3.0 Unported License](https://creativecommons.org/licenses/by-nc-nd/3.0/).

### Address

University of Iowa  
Roy J. and Lucille A. Carver College  
of Medicine  
Department of Ophthalmology and  
Visual Sciences  
200 Hawkins Drive  
Iowa City, IA 52242

[Support Us](#)

### Legal

Copyright © 2019 The University of  
Iowa. All Rights Reserved  
[Report an issue with this page](#)  
[Web Privacy Policy](#) |  
[Nondiscrimination Statement](#)

### Related Links

[Cataract Surgery for Greenhorns](#)  
[EyeTransillumination](#)  
[Gonioscopy.org](#)  
[Iowa Glaucoma Curriculum](#)  
[Iowa Wet Lab](#)  
[Patient Information](#)  
[Stone Rounds](#)  
[The Best Hits Bookshelf](#)

### EyeRounds Social Media

Follow



Receive notification of new cases,  
[sign up here](#)  
[Contact Us](#)  
[Submit a Suggestion](#)